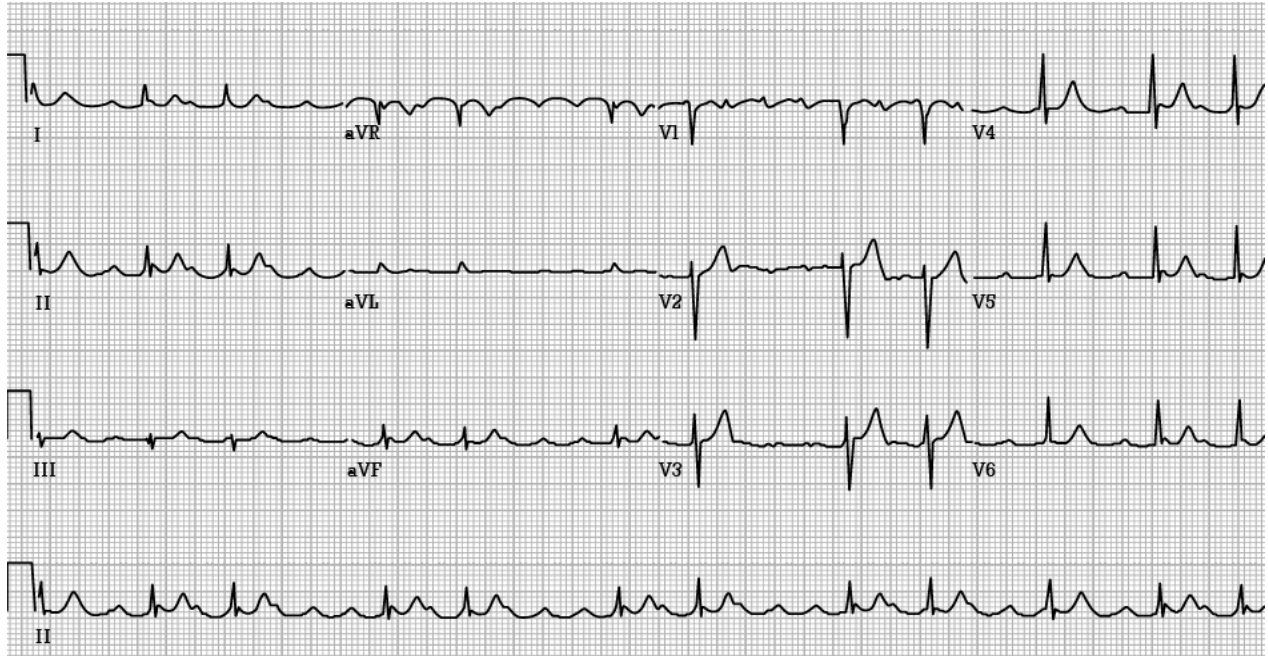


## ERRATUM

In *Electrocardiography in Emergency, Acute, and Critical Care*, 2<sup>nd</sup> Edition, 2019, ISBN 978-1732748606 (Print), Figure 4.3 on page 58 is wrong. The correct image and legend are below.



**FIGURE 4.3.** Atrial tachycardia with variable AV block. This ECG demonstrates rapid, regular atrial tachycardia with a rate of 215/minute, most easily seen in the lead II rhythm strip. The ventricular response is slower and irregular, implying a variable degree of AV block (in some areas 2:1, in some areas 3:1, etc.). Atrial tachycardia with variable AV block, sometimes referred to as "paroxysmal atrial tachycardia (PAT) with block," is commonly encountered in cases of digoxin toxicity, as was the case here. Reproduced with permission from: Amal Mattu, MD, FACEP.